

EndoCal 10 Obturation Voids in Root Canal and Isthmus of a Human Premolar: A Synchrotron micro-CT Imaging Study

Assem Hedayat¹ and Pengyu Wu²

¹College of Dentistry, University of Saskatchewan, 105 Wiggins Rd., Saskatoon, Canada

²Department of Physics and Engineering Physics, University of Saskatchewan, 116 Science Place, Saskatoon, Canada

Keywords: Apex, Isthmus, Synchrotron-Radiation-based X-ray, micro-CT, Endodontic Therapy, Root Canal, EndoCal 10.

Abstract: The objective of this research is to detect and characterize voids in an Endocal 10 obturated human premolar using synchrotron-radiation-based micro-computed tomography (SR μ CT) and 3D visualization. Also, the aim is to investigate the extent of voids present in a fine structure such as an isthmus following obturation. We scanned an extracted human premolar that was obturated with EndoCal 10 using the Bio-Medical Imaging and Therapy (BMIT) 05ID-2 beamline at the Canadian Light Source. We applied the non-destructive monochromatic X-ray beam at 47 keV, and compiled 4.3 μ m pixel size images utilizing a AA-40 (HAMAMATSU) beam monitor synchronized with a (HAMAMATSU C9300-124) charge-coupled camera. We used Fiji for reconstructing the images and Avizo 9.0 for 3D rendering. The results showed voids in different parts of the obturation as well as a partially obturated isthmus. Micro-CT and 3D visualization show that voids exist in the pulp chamber, root canal, and isthmus following obturation with EndoCal 10 during endodontic therapy. We categorized the isthmus as a type V one. The study also highlights the reasons contributing to the difficulty of obturating the isthmus. The variation in isthmus' diameter, its irregular branching, the presence of pulp tissue, as well as its angular orientation with respect to the root canals are some of the reasons that impede the flow of EndoCal 10 through it.

1 INTRODUCTION

EndoCal 10 is a calcium oxide based material used in endodontic therapy. In order to obturate a root canal, a blend of calcium oxide, zinc oxide, and an excipient is mixed with water and ethylene glycol and applied (ALBUCA[®], 2007). The reactions taking place lead to the expansion of the EndoCal as it cures (Guigand et al. 1997, Goldberg et al. 2004). Studies concluded that EndoCal 10 is an effective sealant in endodontic therapy (Goldberg et al. 2004, Ghaziani and Sadeghi 2008).

The criterion to evaluate the obturation totality of a material during endodontic treatment is the adequacy of filling root canals. It was concluded from a micro-CT study that different obturating materials exhibited a certain degree of voids present. These inadequacies in obturation occurred at a significantly higher degree in the apical region of the teeth (Wolf et al. 2014).

In general, root canal isthmuses are prevalent in human teeth and are classified into different types

(Hsu and Kim 1998). The presence of tissue remnants and the associated microorganisms in these isthmuses may affect the success of endodontic therapy. It is indispensable to seal off isthmuses during endodontic treatment (Von Arx, 2005). The use of micro-CT to characterize the obturation of Isthmuses showed partial filling that may have been caused by debris from hard tissue and remnants of pulp tissue (Oh et al. 2016).

There are no micro-CT studies that were pursued to delineate the obturation characteristics of EndoCal 10 inside the tooth structure where it is applied. Examples of these structures are root canal apices and isthmuses. The objective of this research is to delineate the degree of adequacy of Endocal 10 as an obturating material during endodontic therapy using the micro-CT capability of the Bio-Medical Imaging and Therapy (BMIT) 05ID-2 beamline at the Canadian Light Source, and to characterize the voids present in an isthmus and a root canal.

This is a pilot study based on a case where the extracted human premolar was obturated with

EndoCal 10. Accordingly, we did not pursue a comparison with more teeth and other materials used in endodontic treatment.

2 METHODS

2.1 Premolar Endodontic Therapy

The two-rooted extracted human premolar used in this study was amongst 12 other teeth selected from the tooth bank (College of Dentistry, University of Saskatchewan) and screened for having intact roots as examined by a conventional X-ray machine (Carestream CS2200, Carestream Health Inc., Vaughan, Canada). We stored the premolar in Carolina solution (Carolina Biological Supply Company, Burlington, NC, USA) at all times. We summarize the endodontic therapy that was pursued as follows:

1. We used a high-speed driven endodontic diamond bur to penetrate the pulp chamber.
2. We utilized a sequence of stainless steel Kerr Dental K-Flex endo hand files sizes 10, 15, 20, and 25 Kerr, Orange, CA, USA) to widen the root canals.
3. Irrigation with 5.25% sodium hypochlorite was necessary after applying every file.
4. The crown-down technique was then carried out employing SybronEndo K3 Engine Files (K Dental Inc., Markham, ON, Canada) lubricated with Glyde File-Prep RC Conditionar (Patterson Dental, St. Paul, MN, USA). Irrigation and drying were always carried out after every file.
5. We then applied EndoCal 10 (ALBUCA, Montreal, QC, Canada) using a Lentulo spiral to obturate the premolar.
6. Finally, we etched the inner walls of the premolar above the obturation with 37% phosphoric acid, rinsed it, dried it, covered it with 3M Scotchbond Universal Adhesive (3M ESPE, St. Paul, MN, USA), and restored it with 3M Filtek Supreme composite (3M ESPE, St. Paul, MN, USA).

2.2 Synchrotron Scanning

We scanned the premolar using the Bio-Medical Imaging and Therapy (BMIT) 05ID-2 beamline at the Canadian Light Source (CLS). We followed the same procedure detailed in one of our previous studies (Hedayat et al. 2016). In this work, we subjected the premolar to the non-destructive monochromatic X-ray beam at 47 keV, and compiled 4.3 μm pixel size

images utilizing a AA-40 (HAMAMATSU) beam monitor synchronized with a (HAMAMATSU C9300-124) charge-coupled camera.

2.3 Image Reconstruction and 3D Rendering

We used Fiji for reconstructing the images and Avizo 9.0 (FEI, Hillsboro, OR, USA) for 3D rendering. We have used Avizo 9.0 in a previous study (Hedayat et al. 2016), and found it a powerful tool for analyzing micro-CT acquired data.

3 RESULTS

We used Avizo 9.0 for 3D visualization of the premolar, and observed three distinct features in the images: a vertical fracture along the side of one of the roots, voids within the obturated pulp chamber and apex of the nonfractured root, and partial obturation within the isthmus between the two root canals. Since we have already prepared a manuscript identifying and analyzing the cause of the vertical fracture along one side of one of the roots, the latter two observations are addressed in this manuscript.

3.1 Voids in EndoCal 10 Obturated Structures

It is clear from Figure 1(a) and (b) that one root fractured while the other one exhibited obturation voids at its apex. Arrow A points toward the void while arrow B points to the fractured root.

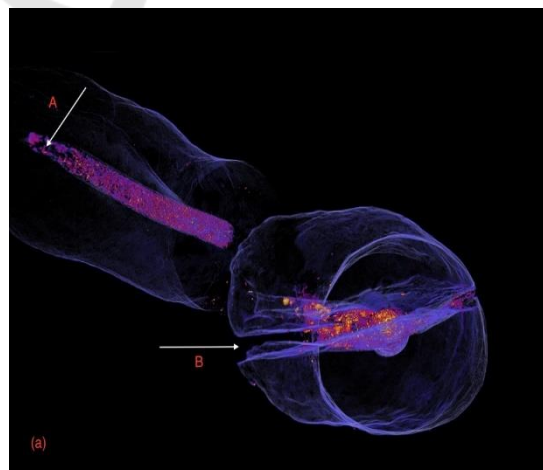


Figure 1(a): Two roots of the premolar, one exhibiting a crack while the other showing obturation inadequacy at its apex.

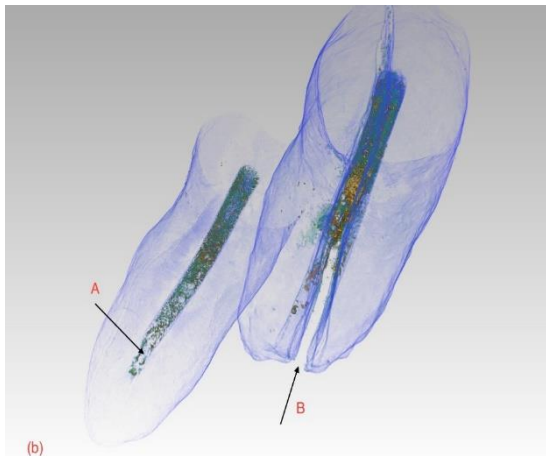


Figure 1(b): Two roots of the premolar, one exhibiting a crack while the other showing voids within the obturation at its apex.

The voids in EndoCal 10 were not limited to the apex of the root, but were also present in areas within the obturated pulp chamber as shown in Figure 2(a). The arrow “V” points to the void within the axial section, as well as on the gray value profile plot in Figure 2(b).

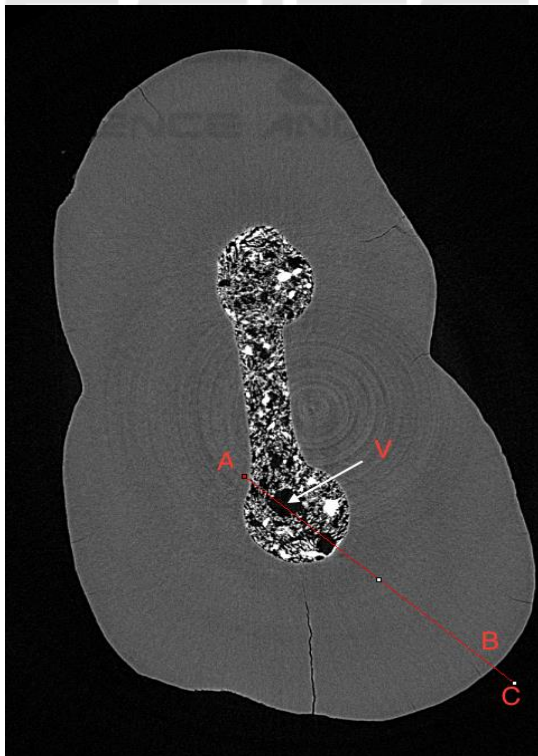


Figure 2(a): Axial section of the pulp chamber showing void “V”.

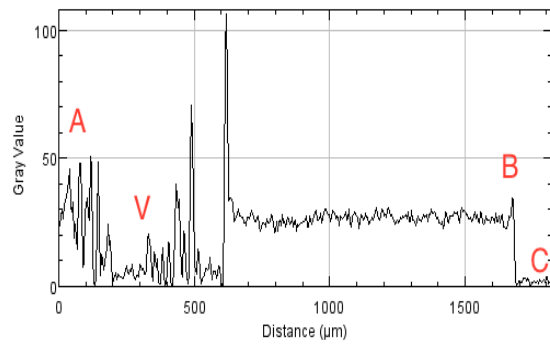


Figure 2(b): Gray value profile plot reflecting the features along the line in Figure 2(a) and especially void “V”.

3.2 Partial Obturation of Isthmus

We used Avizo 9.0 for 3D rendering of an isthmus within the premolar. The arrow in Figure 3 points to the isthmus which extends between the two root canals. We were interested to learn about the extent of EndoCal obturation through the isthmus, and accordingly compiled a series images of sagittal and axial sections of the area surrounding it.




Figure 3: Isthmus between the two root canals of the premolar.

Figure 4(a) to 4(g) is a series of images of sagittal sections illustrating the extension of the isthmus between the two root canals. The arrows in all images point to the isthmus. All images showed the EndoCal as it partially obturated the isthmus from the left side. It is significant to mention that some of the sagittal and axial sections showed the presence of tissue within the isthmus. For example, in Figure 4(e), while arrows “A” and “B” point to the isthmus structure, arrow “C” points to the tissue inside the isthmus. The

appearance of the Endocal tissue inside the isthmus is different and clearly distinguishable from that of EndoCal 10.

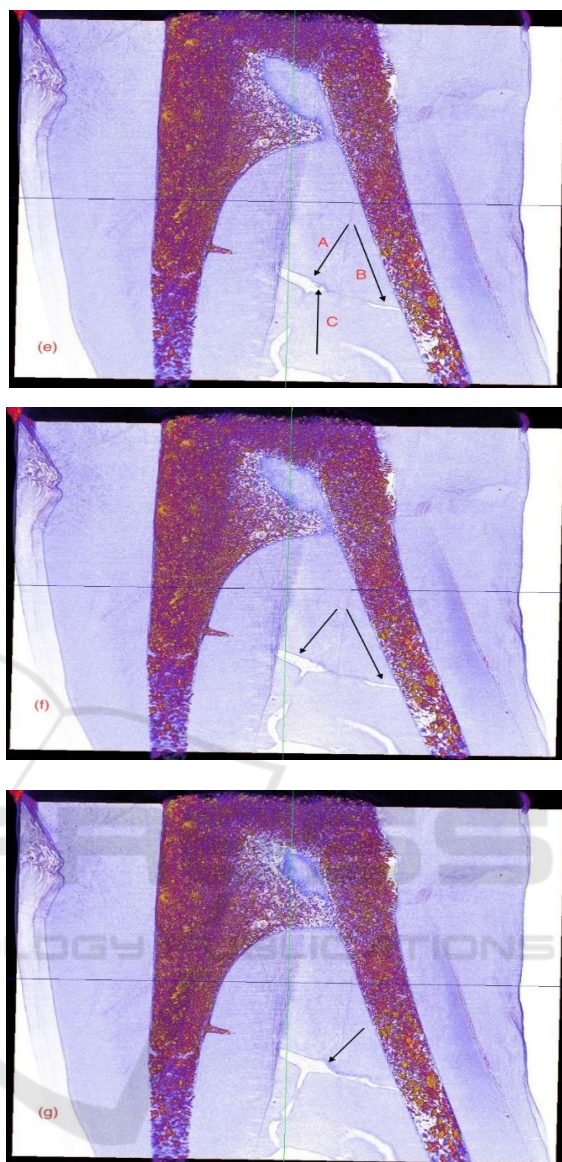
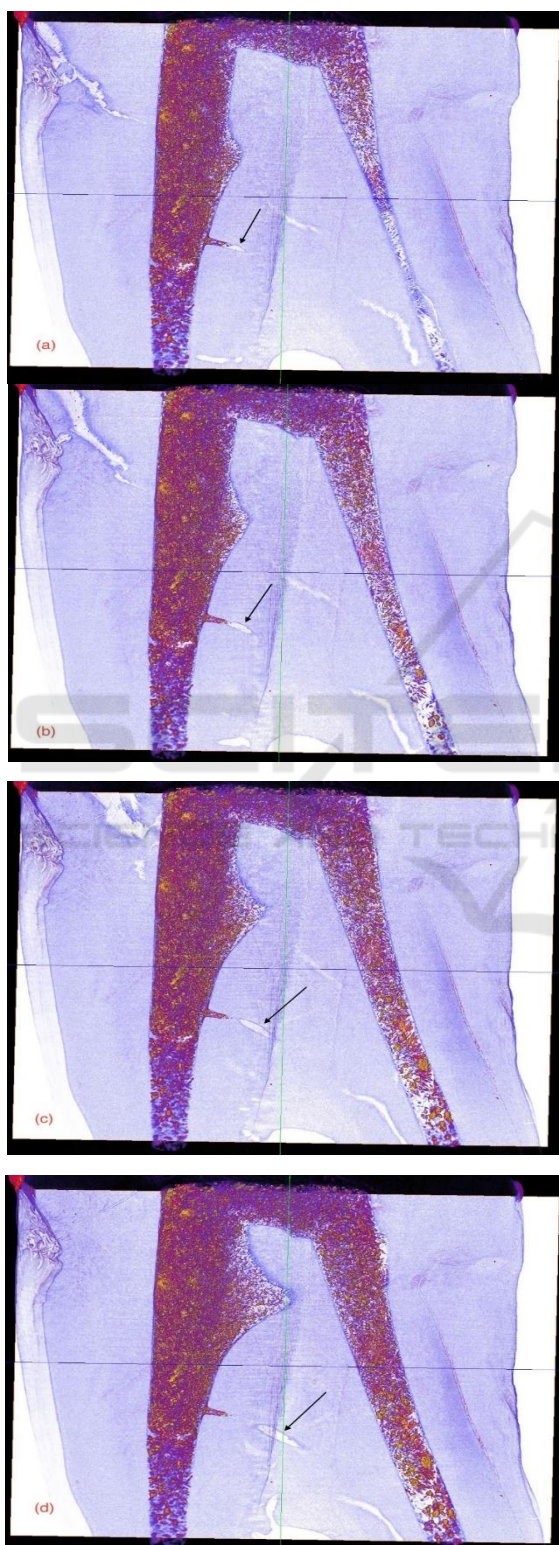


Figure 4 (a) to (g): Series of Sagittal sections showing partial obturation of the isthmus by EndoCal 10.

The axial section in Figure 5(a) illustrates the partial obturation of the isthmus at one end with EndoCal 10. The profile plot of gray value in Figure 5(b) shows the presence of EndoCal 10 at the peak "B". In contrast, the axial sections in Figures 6(a) and 7(a) shows the absence of EndoCal 10 at point "B", which is also reflected in the profile plots of the gray value in Figures 6(b) and 7(b).

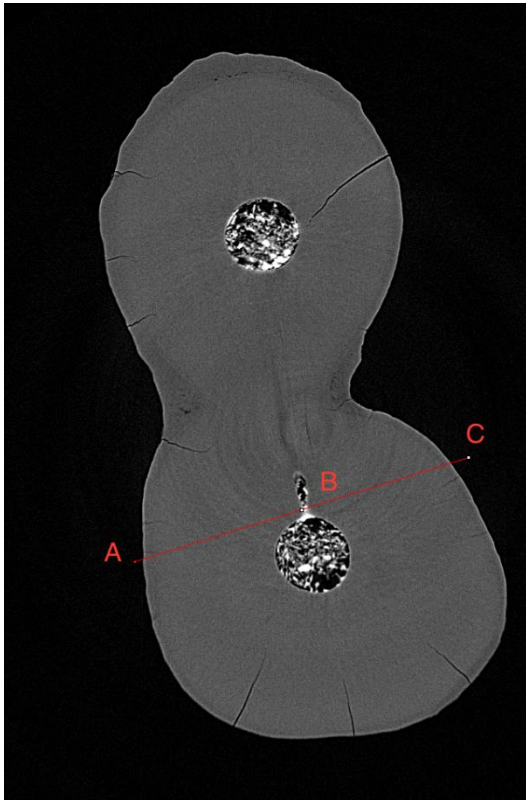


Figure 5(a): Axial section showing EndoCal 10 partially obturating the isthmus.

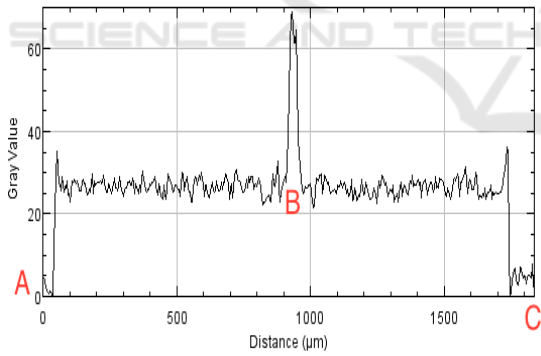


Figure 5(b): Profile plot of gray value reflecting the features along the line in 5(a).

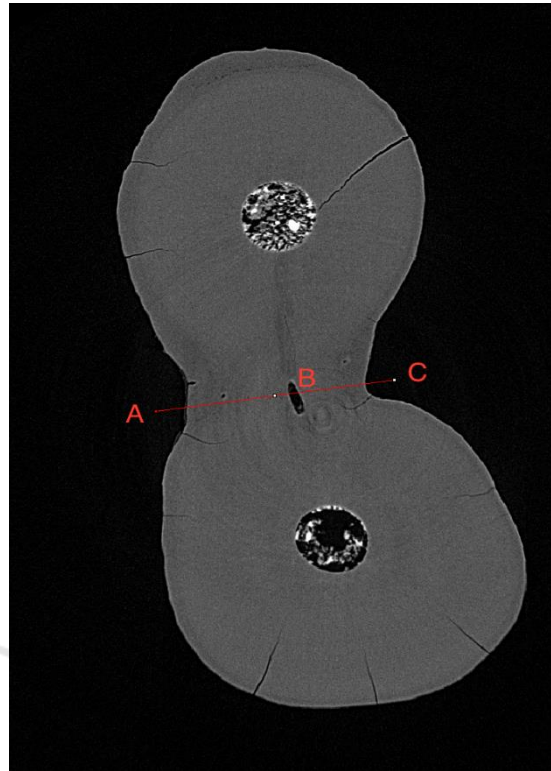


Figure 6(a): Axial section showing the isthmus.

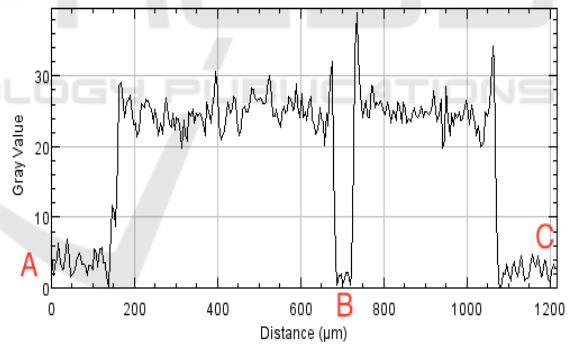


Figure 6(b): Profile plot of gray value reflecting the features along the line in 6(a).

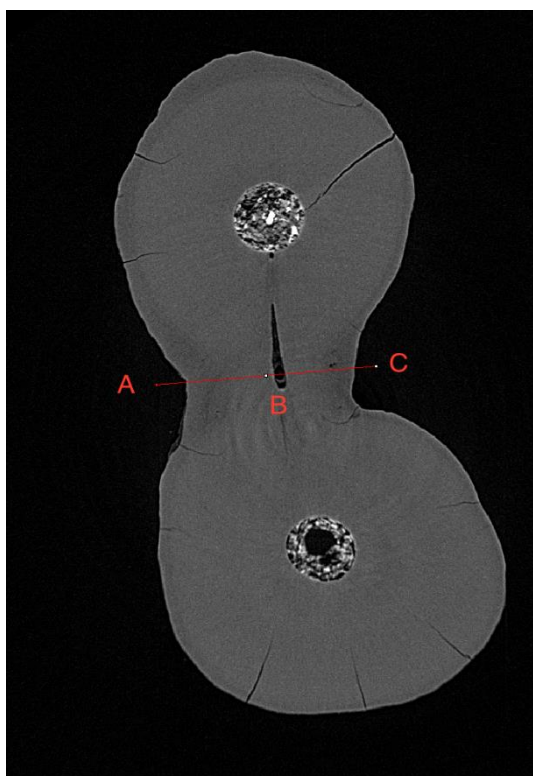


Figure 7(a): Axial section showing the isthmus.

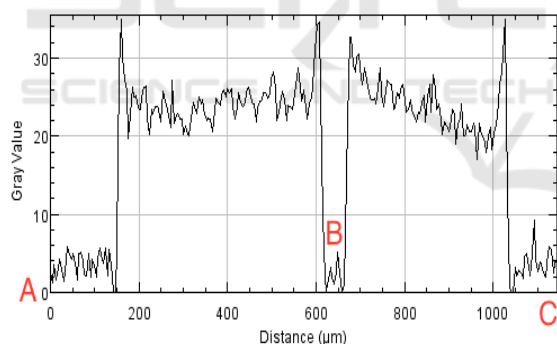


Figure 7(b): Profile plot of Gray value reflecting the features along the line in 7(a).

4 DISCUSSION

Through synchrotron-radiation-based micro-computed tomography (SR μ CT) and 3D rendering, we achieved the objective of delineating voids in an extracted human premolar obturated with EndoCal 10. Using this non-destructive technique, we also accomplished the aim of studying the degree of void prevalence in an isthmus post obturation with Endocal 10.

The high degree of fluidity of EndoCal 10 during thorough mixing of its powder and liquid components clearly suggests that the material has the capability to flow throughout the prepared structures and obturate them adequately during endodontic therapy. Although this was observed in crevices and cracks through 3D visualization at high resolution, there were voids in the obturation in some areas of the pulp chamber and apex of one root. Figure 1(b) and 2(a) show the voids present in the pulp chamber and root apex, respectively. This supports what was reported earlier (Wolf *et al.* 2014) that obturating materials exhibit some degree of voids present. In this case, the voids may be attributed to the entrapment of air bubbles during the obturation process. This also signifies that although Endocal 10 expands following its mixing and activation, the expansion does not engulf and fill the gaps completely.

Visualizing the isthmus between the root canals at a high resolution and in 3D, as shown in Figure 3, we concluded the following:

1. The isthmus is a continuous one connecting both root canals, and accordingly can be classified as a type V isthmus as defined in the literature (Hsu & Kim 1998).
2. Some 2D and 3D images showed remnants of pulp tissue inside the isthmus.
3. The isthmus was partially obturated and Endocal 10 was able to flow to a certain extent from one end as shown in the series of images in Figure 4. This is an indication that no hard debris resulting from the preparation of the root canals plugged the isthmus.
4. Through 3D visualization, we observed that the geometry of the isthmus is tubular in structure. It is narrow at the root canal connecting ends and has dead-end branches emerging from it. The isthmus' diameter increases to a maximum in between its two ends, which causes a pressure drop in the Endocal's flow through it. The pressure drop is an impeding factor to the flow of Endocal 10 through the isthmus.
5. As shown in Figures 3 and 4g, the isthmus is slanted downwards from the left root canal to the right one. Accordingly, it was easier for the EndoCal to flow downwards and partially obturate the isthmus at the left end, rather than flow upwards at the right end.

This is a single case pilot study that we plan to expand on in the future. We plan to pursue a comparative study that includes several teeth obturated with Endocal 10. We also plan to study the obturation inadequacies in teeth using other materials

during endodontic treatment. We will apply the same techniques in data acquisition and processing as we did in this study.

5 CONCLUSIONS

1. Similar to other obturating materials used in endodontic therapy, voids may appear in parts of the pulp chamber, apical region of the root canal, and isthmus following the application of EndoCal 10.
2. As illustrated through 3D rendering, the root canal isthmus in this study is characterized by a non-uniform diameter, branches, and tissue within it.
3. With conventional endodontic therapy, it is not possible to completely obturate an isthmus with a structure similar to the one visualized in this study. This is attributed to its varying diameter, its branching architecture, and the tissue remaining in it.
4. Through 3D visualization of the isthmus between the two root canals in this study, we categorize this isthmus as a type V.

6 FUTURE WORK

1. Future work, that will be comparative in nature, is planned to apply the imaging technology and 3D rendering technique we followed in this study to more cases of teeth obturation with Endocal 10 during endodontic therapy. The research will delineate the voids in the obturated roots, and evaluate the degree of obturation in the isthmuses that might be present in those teeth.
2. It will be of value to pursue the study on other obturating materials used in endodontic treatment. The results will be also compared.
3. We can quantify the volume of voids and compare the data acquired from different teeth and using other obturating materials in future studies.

ACKNOWLEDGEMENTS

Research described in this paper was performed at the BMIT facility at the Canadian Light Source, which is

supported by the Canada Foundation for Innovation, Natural Sciences and Engineering Research Council of Canada, the University of Saskatchewan, the Government of Saskatchewan, Western Economic Diversification Canada, the National Research Council Canada, and the Canadian Institutes of Health Research.

We thank Dr. Ning Zhu for his guidance and assistance throughout our research at (BMIT) 05ID-2 beamline at the Canadian Light Source.

REFERENCES

- ALBUCA© (2007) [WWW document] URL http://www.albuca.com/english/albuca_endocal.html [accessed on 9 July 2017].
- Goldberg R A, Kuttler S, Dorn S O (2004) The properties of Endocal 10 and its potential impact on the structural integrity of the root. *Journal of Endodontics*, 30(3), 159-162.
- Ghaziani P, Sadeghi Gh (2008) An in vitro comparison of apical leakage of Biocallex, white TMA, gray MTA, and amalgam as root-end fillings. *Journal of Dentistry of Tehran University of Medical Sciences*, 5(3), 131-135.
- Guigand M, Vulcain J M, Dautel-Morazin A, Bonnaure-Mallet M (1997) An ultrastructural study of root canal walls in contact with endodontic biomaterials. *Journal of Endodontics* 23(5), 327-330.
- Hedayat A, Nagy N, Packota G, Monteith J, Allen D, Wysokinski T, Zhu N (2016) Synchrotron-radiation-based X-ray micro-computed tomography reveals dental bur debris under dental composite restorations. *Journal of Synchrotron Radiation*, 23, (777-782).
- Hsu Y Y, Kim S (1997) The resected root surface. The issue of canal isthmuses. *Dental Clinics of North America*, 41(3), 529-40.
- Oh S, Perinpanayagam H, Kum D J W, Lim S-M, Yoo Y-J, Chang S W, Lee W, Baek S-H, Zhu Q, Kum K Y (2016) Evaluation of three obturation techniques in the apical third of mandibular first molar mesial root canals using micro-computed tomography. *Journal of Dental Sciences*, 11, 95-102.
- Von Arx T (2005) Frequency and type of of canal isthmuses in first molars detected by endoscopic inspection during periradicular surgery. *International Endodontic Journal*, 38, 160-168.
- Wolf M, Kupper K, Reimann S, Bourauel C, Frentzen M (2014) 3D analyses of interface voids in root canals filled with different sealer materials in combination with gutta-percha technique. *Clinical Oral Investigations*, 18, 155-161.