

Feasibility of Eye-tracking based Glasses-free 3D Autostereoscopic Display Systems for Medical 3D Images

Dongwoo Kang, Seok Lee, Hyoseok Hwang, Juyong Park, Jingu Heo, Byongmin Kang,
Jin-Ho Lee, Yoonsun Choi, Kyuhwan Choi and Dongkyung Nam
Multimedia Processing Lab, Samsung Advanced Institute of Technology, Suwon-si, South Korea

Keywords: Three-dimension, 3D, Glasses-free 3D Autostereoscopy, Eye-tracking, Medical 3D, Cardiac CT, Coronary CTA, 3D Heart, Display.

Abstract: Medical image diagnosis processes with stereoscopic depth by 3D display have not been developed widely yet and remain understudied. Many stereoscopic displays require glasses that are inappropriate for use in clinical diagnosis/explanation/operating processes in hospitals. An eye-tracking based glasses-free three-dimensional autostereoscopic display monitor system has been developed, and its feasibility for medical 3D images was investigated, as a cardiac CT 3D navigator. Our autostereoscopic system uses slit-barrier with BLU, and it is combined with our vision-based eye tracking system to display 3D images. Dynamic light field rendering technique is applied with the 3D coordinates calculated by the eye-tracker, in order to provide a single viewer the best 3D images with less x-talk. To investigate the feasibility of our autostereoscopic system, 3D volume was rendered from 3D coronary CTA images (512 by 512 by 400). One expert reader identified the three main artery structures (LAD, LCX and RCA) in shorter time than existing 2D display. The reader did not report any eye fatigue or discomfort. In conclusion, we proposed a 3D cardiac CT navigator system with a new glasses-free 3D autostereoscopy, which may improve diagnosis accuracy and fasten diagnosis process.

1 INTRODUCTION

Three-dimensional (3D) medical imaging techniques are increasingly employed for evaluation of not only identifying complex organ structures but also diagnosing abnormalities. Recent advanced 3D imaging techniques such as MR, CT and Ultrasound showed the usefulness and evoked the demand of 3D medical imaging displaying system. Also 3D graphics techniques have been developed fast, which enables high quality 3D medical volume rendering (Chan et al., 2013, Ferroli et al., 2013, Langdon et al., 2014). However, the advanced and complex 3D medical images are displayed with 2D monitors, where 3D objects are projected into 2D plane.

3D displays have become available these days. Especially, three-dimensional movies presented via stereoscopic displays have become more popular in recent years aiming at a more engaging viewing experience. However, medical image diagnosis processes with stereoscopic depth by 3D display have not been developed widely yet and remain

understudied.

Additionally, many stereoscopic displays require glasses that are inappropriate for use in clinical diagnosis/explanation/operating processes in hospitals. A few studies of 3D autostereoscopy in medical image analysis area exist (Narita et al., 2014).

A glass-free 3D autostereoscopic display monitor has been developed by Samsung Advanced Institute of Technology (SAIT) (Park and Nam, 2012, Park et al., 2013) which provides almost same 3d quality as 3D display that requires 3D glasses: $\leq 5\%$ crosstalk.

We investigated "3D display needs" from medical doctors in various medical departments from Samsung Medical Center (SMC). Based on the collected opinions, we developed a new application of glass-free medical 3D: Cardiac CT 3D Navigator.

One of the medical imaging systems that require 3D display system is cardiac CT due to complex anatomy of a heart and isotropic 3D volume of cardiac CT. 3D display for cardiac CT diagnosis without glasses techniques may enable physicians and medical doctors to make a detailed/accurate

diagnosis and facilitate diagnosis processes.

In this paper, we introduce our glasses-free autostereoscopic display to medical society, and discuss the feasibility as a medical 3D display, which may help improved diagnosis accuracy and fastened diagnosis process, with an application with cardiac CT data.

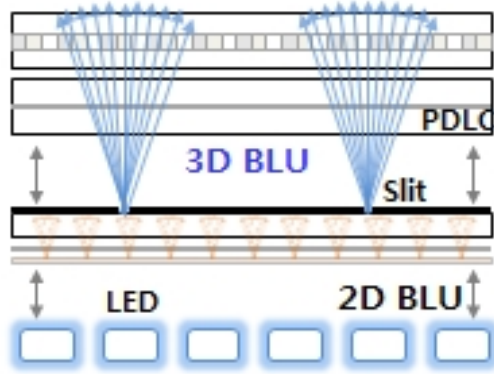


Figure 1: Slit-barrier with BLU composition.

2 METHOD

We developed a new 3D diagnosis system with a new glasses-free display technique. The new glasses-free display system is based on eye-tracking technique and slit-barrier with back light unit (BLU) device technique. The new system was applied to 3D cardiac CT, for a new glass-free cardiac CT 3D navigator system.

2.1 Eye-tracking based Glasses-free 3D Autostereoscopic Display

Our 3D display consists of display panel, optical element for 3D and camera. The 4K liquid crystal display (LCD) panel was used. The optical element for 3D device is a device that controls the direction of lights which pass through the panel, where our display system is based on slit-barrier with BLU technique. The slits in the barrier allow only left image pixels to pass into left eye position, right image pixel to pass into right eye position. Our slit-barrier locates behind LCD panel and in front of BLU (Figure 1).

The camera is used for eye-tracking, where machine learning based eye-tracking algorithm was applied. With this eye-tracking algorithm, the viewer doesn't have to find the good position to see the 3D properly, but can see the 3D in any position that tracking is allowed. The eye-tracker identifies the

viewer's the 3D coordinates of the pupil center, the subpixel values for the left and right views in display panel are adjusted to be seen correctly by viewer's eyes.

The real-time machine learning based eye-tracking algorithm starts from face detection using the AdaBoost learning algorithm (Freund and Schapire, 1997). From the detected face region, subregions with eyes are extracted by shape alignments using Supervised Descent Method (SDM) (Xiong et al., 2013). 23 landmark points of eyes, nose and mouth were used for SDM shape alignments.




Figure 2: 3D rendering techniques. Our autostereoscopy uses dynamic light field mapping method.

3D Light ray image is generated by a 3D rendering algorithm, where each pixel's light ray direction was determined by the slit-barrier. Especially, based on eye tracking algorithm, Dynamic Light Field Mapping (DLFM) is applied for the 3D rendering (Park and Nam, 2012, Park et al., 2013). Using the position and direction information of each light, each light is mapped to the 3D eye coordinates. While Dynamic View Mapping (DVM) 3D rendering method (Boev et al., 2008), which many vendors uses currently just switches left/right images according to the eye position, DLFM maps each light ray to eye coordinates (Figure 2). Because a DLFM technique utilizes the photorefractive effect of each ray, viewer can see the 3D images without the limitation of viewing distance. Also DLFM can solve

the image degradation problem of large 3D displays. The overall specification of our 3D autostereoscopic system is shown in Table 1, and the prototype of our display is shown in Figure 3.

Table 1: Eye-tracking based autostereoscopic display system specification.

Panel size	31.5 Inch
2D resolution	3840x2160
3D resolution	1536x720
Viewing distance	100cm±50cm
Viewing Angle	H60°/V40°
User	1 person only
Frame Rate	60Hz

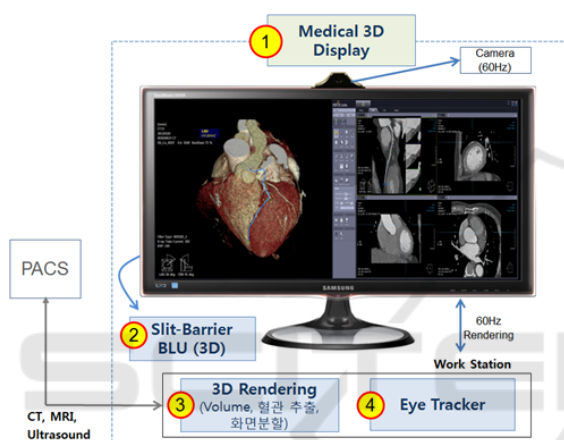


Figure 3: Prototype of eye-tracking based autostereoscopic display system for medical 3D.

2.2 3D Cardiac CT Navigator: 3D Autostereoscopy Visualization Feasibility

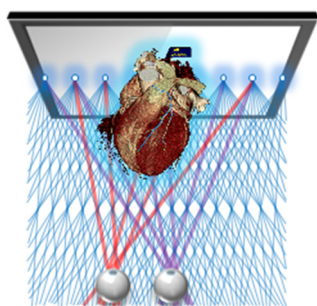


Figure 4: 3D cardiac CT navigator concept.

3D coronary CT angiography (CTA) images were visualized with our 3D eye-tracking based 3D autostereoscopic display system. Under advice of medical doctors at SMC, we made a 3D cardiac CT

navigator software. A 3D CTA anonymized image data was obtained from SMC. The CTA dataset was acquired on the dual-source 64-slice CT scanner (Definition Siemens Medical Solution, Germany) with a gantry-rotation time of 330ms and standard collimation of 0.6mm, and had excellent image quality. 3D CTA scan parameters were 512x512 matrix, voxel size 0.38x0.38x0.3mm³, and 412 slices. The patient did not have any luminal stenosis or plaque.

The proposed navigator system aims identifying the 3D structure of the complex organs easily, and we developed a 3D cardiac CT navigator proto as an example (Figure 4). With help of enhanced 3D depth perception in our 3D display, viewers can recognize the complex 3D structure in depth.

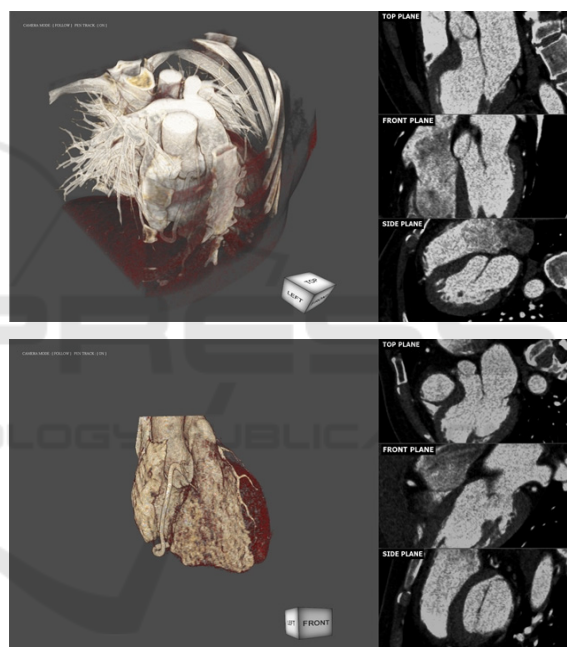


Figure 5: 3D cardiac CT navigator S/W proto. Original CT volume is rendered without any segmentation (up) and whole segmentation (down).

For 3D visualization, we followed the standard cardiac CT image and graphics processing from a coronary CTA image dataset: (1) whole heart segmentation, (2) coronary artery segmentation, and (3) 3D volume rendering. User can adjust the color and transparency of 3D volumes by option. Also, multi-planar reconstruction (MPR) is aligned with 3D volume rendering by side (Figure 5). Further, our software has an option of converting the volume to 3D mesh, which graphics artists can decorate manually.

One expert reader from SMC was asked to

identify the structure of heart with our 3D autostereoscopy. In a segmented heart only 3D volume, the expert reader identified main heart structures including three main coronary artery structures (LAD, LCX and RCA).

3 RESULTS AND DISCUSSION



Figure 6: Eye-tracking for 3D autostereoscopy.

A 3D coronary CTA image was tested with our 3D glasses-free autostereoscopic display system and 3D cardiac CT navigator software. The average error of the eye-tracking was 2mm, which was calculated as Euclidean distance between the center of pupils and tracked eye coordinates (Figure 6). Also the tracking time of eyes was 16ms in average. The average crosstalk of our 3D display was 4.9%, which was similar 3D quality to that of 3D display with glasses. With dynamic light field rendering method, 2 stereo images (left and right images) were generated for 3D display, making the depth 20cm (Figure 7). A standard 2.5 GHz personal computer running windows 7 was used for running the cardiac software. The rendered 3D heart volume is 3D light field rendered by dynamic light field mapping method for displaying in our 3D autostereoscopy. All the processes ran in the real time.

The expert reader visually assessed the quality of our 3D autostereoscopy. He did not report any eye fatigue or discomfort. Also, he identified the 3D heart structure with our 3D autostereoscopy, including 4 chambers, aorta, main coronary arteries (LAD, LCX and RCA). He didn't provide the quantity assessment but reported he could identify the 3D structure faster and easier. Further investigation is required with quantification for testing usefulness of our 3D autostereoscopy: this is a limitation of our study. Also number of cases

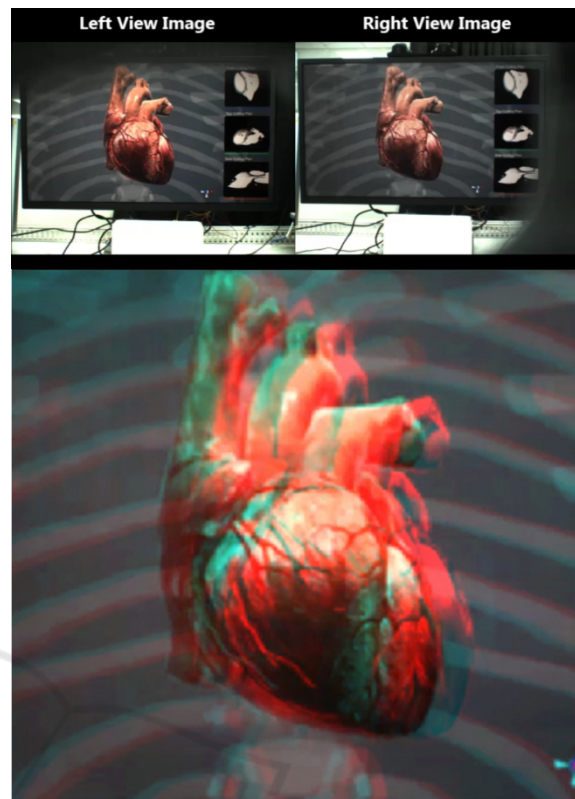


Figure 7: Stereo images from 3D mesh for a 3D CT volume (up) and generated anaglyph (down). A graphics artist decorated the heart manually.

4 CONCLUSIONS

We proposed a 3D cardiac CT navigator system with our new glasses-free 3D autostereoscopy. We introduced the feasibility of 3D autostereoscopy for medical image diagnosis. It may improve diagnosis accuracy and fasten diagnosis process. Our 3D autostereoscopic system can be applied any 3D volumetric medical images.

ACKNOWLEDGEMENTS

We thank Dr. Jinho Choi at Samsung Medical Center (SMC) for all the advice for the medical 3D navigator system.

REFERENCES

Chan, S., Conti, F., Salisbury, K. & Blevins, N. H., 2013, Virtual reality simulation in neurosurgery: technologies

- and evolution, *Neurosurgery*, 72(1), 154-164.
- Ferrolì P., Tringali, G., Acerbi, F., Schiariti, M., Broggi, M. Aquino, D. & Broggi, G., 2013, Advanced 3-dimensional planning in neurosurgery, *Neurosurgery*, 72(1), 54-62.
- Langdon, W. B., Modat, M., Petke, J., Harman, M., 2014, Improving 3D medical image registration CUDA software with genetic programming, *Proceedings of the 2014 Annual Conference on Genetic and Evolutionary Computation*, 951-958.
- Narita, Y., Tsukagoshi, S., Suzuki, M., Miyakita, Y., Ohno, M., Arita, H., Saito, Y., Kokojima, Y., Watanabe, N., Moriyama, N. & Shibui, S., 2014, Usefulness of a glass-free medical three-dimensional autostereoscopic display in neurosurgery, *International Journal of Computer Assisted Radiology and Surgery*, 9(5), 905-911.
- Park, J., Nam, D., 2012, Active light field rendering in multi-view display systems, *SID International Symposium*, 36-39.
- Park, J., Nam, D., Choi, S. Y., Lee, J., Park, D. S., & Kim, C. Y., 2013, Light Field Rendering of Multi-view Contents for High Density Light Field 3D Display, *SID International Symposium*, 667-670.
- Freund, Y., Schapire, R.E., 1997, A Decision-Theoretic Generalization of on-Line Learning and an Application to Boosting, *Journal of Computer and System Sciences*, 119-139.
- Xiong, X., Torre, F. D. L., 2013, Supervised Descent Method and its Applications to Face Alignment, *CVPR*, 532-539.
- Boev, A., Georgiev, M., Gotchev, A. & Egiazarian, K., 2008, Optimized Single-viewer Mode of Multiview Autostereoscopic Display, *EUSIPCO*, 25-29.